

The Mercury “Bullet” at Autopsy

Sarah K. Long

Sam Houston State University, Huntsville, TX

Richard Wiggins, Jennifer Akin, Dr. Amy Gruszecki
American Forensics

Presented at AAFS 68th Annual Scientific Meeting
February 2016



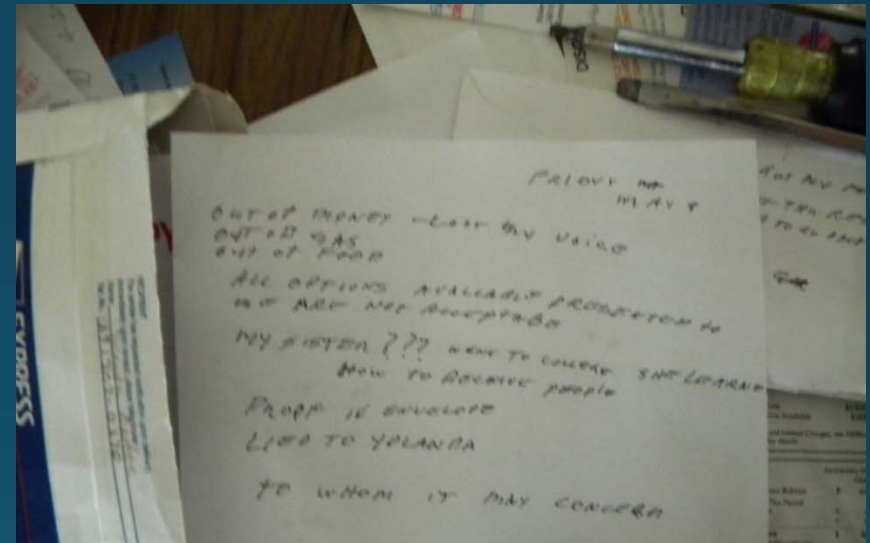

No financial disclosures.
No conflicts of interest.

Case history

- 62 year old male found outside his home in his truck.
- Rural area of Texas.
- Gun was at his side.

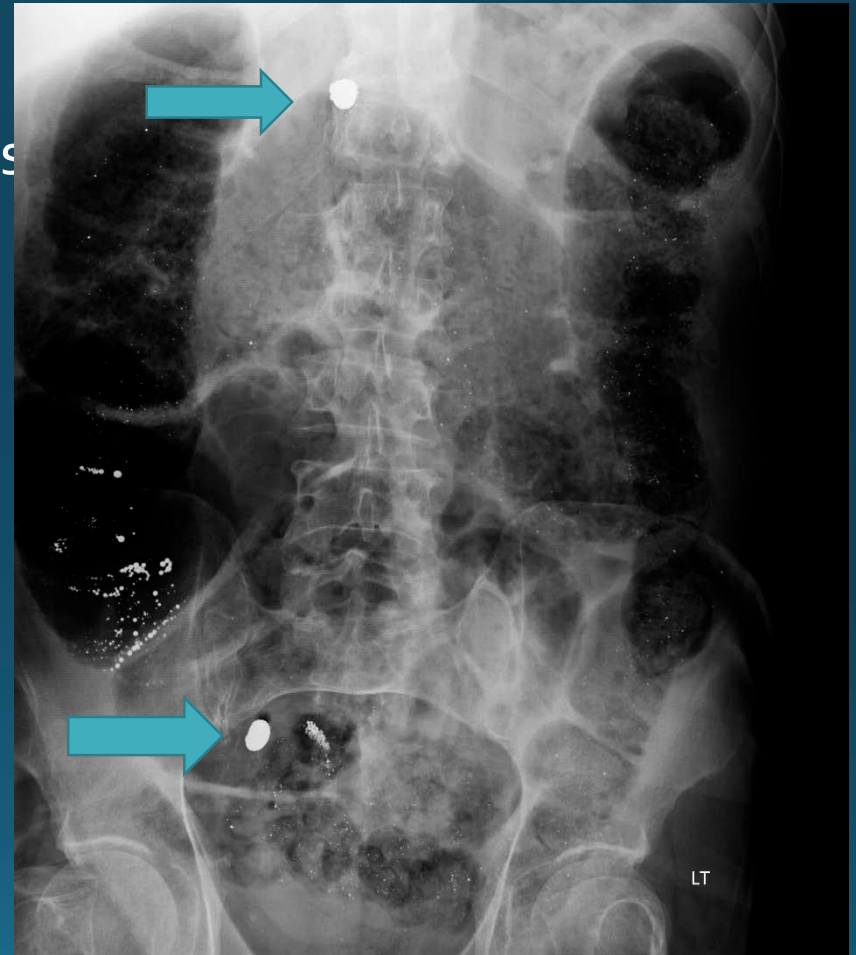


Suicide notes in car and in house



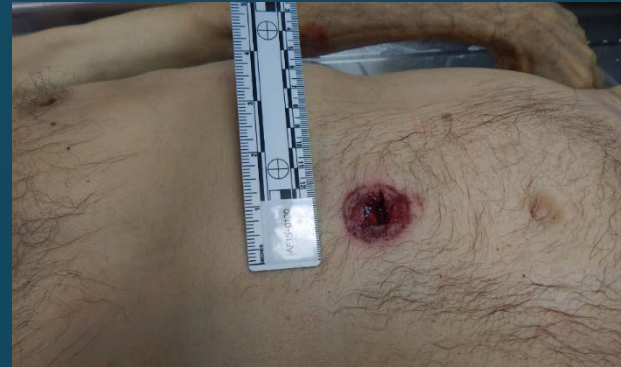Radiograph at autopsy

- Appeared to have 2 projectiles



Autopsy findings

- One external entrance wound
- No exit wounds.
- One projectile identified in vertebral column.
- Path – through pancreas, colon, & vertebral column.
- Hemoperitoneum, large vessels spared.
- Severe HASVCD.



Second “bullet” was not located and no tract was noted – was it a possible “old projectile”

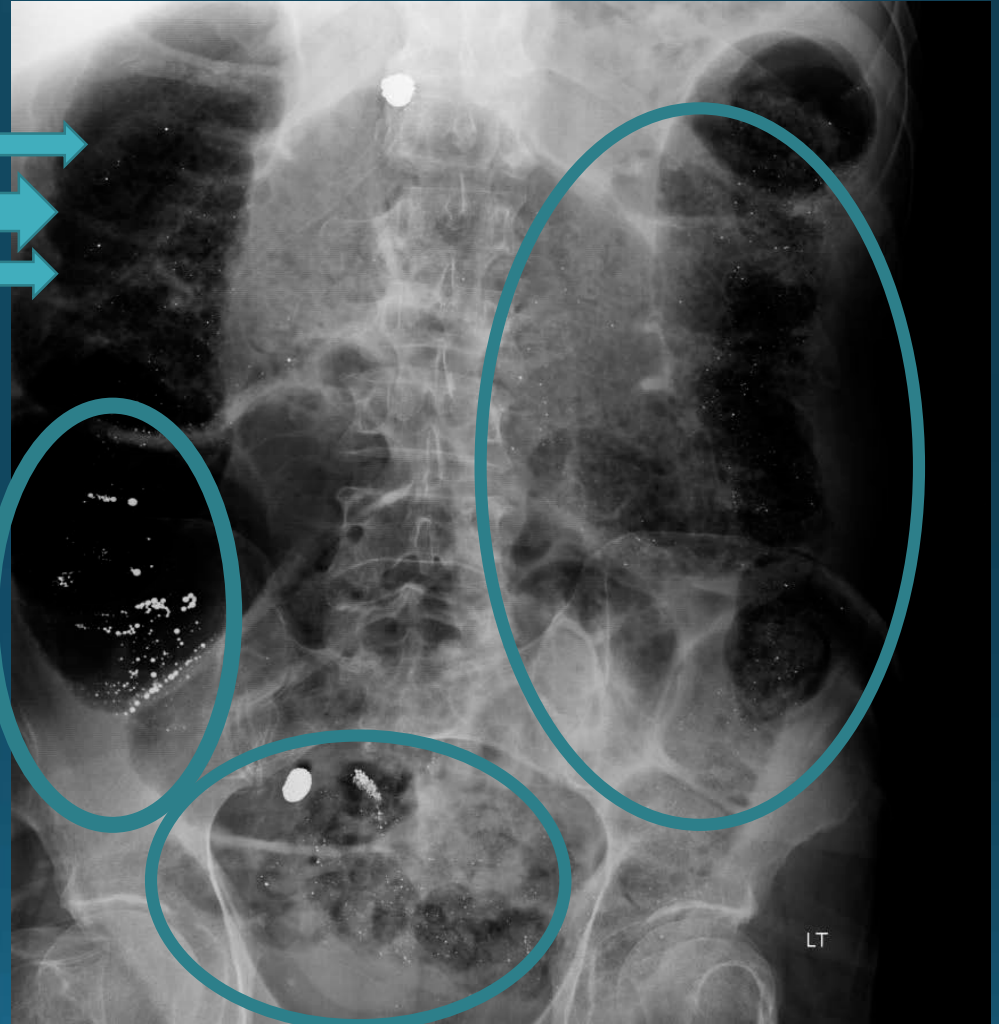
Additional radiographs

- X-ray again— no additional projectiles remaining in body.
- Now what?
- Re-examine 1st x-ray.

Review first x-ray

Multiple radiopaque dots
and specks throughout the
intestines.

Also helpful that tech noticed in
organ bucket accumulation of
liquid metal (Mercury)!!!!



Mercury collected



Where did Mercury come from?

- Bullet – further investigation and research
- Or
- Ingestion – check toxicology

Investigation

- No source of mercury noted on scene.
- Speak with Justice of the Peace
 - Happens to be ex-cop
 - “old army guys tip their ammunition with mercury”
- Internet – many anecdotal stories of mercury being placed in the hollow tip of projectiles to provide an explosion.

Research - Exploding Mercury Bullets

- Mercury - little is reported in the scientific literature regarding this entity.
- Bernard Knight (1982) references that “in 1862 the British army manufactured the Metford Shell-bullet, which used Mercury Fulminate as its detonate” .
- Swift and colleagues (2004) references “handgun cartridges containing Pyrodex charges with or without mercury additives”.

Toxicology analysis on deceased

- Negative toxicology for drugs of abuse and medications.
- Mercury level 33 mcg/L (normal <10 mcg/L)

Effects of Mercury Ingestion

- Chronic exposure can cause
 - nervousness
 - mood swings
 - irritability
 - decreased cognitive function
 - “Mad as a hatter”
- High exposures can cause respiratory failure, renal failure and death.

Lethality of Mercury Ingestion

- Attempted suicide by mercury ingestion infrequently encountered.
- Results in minimal acute toxicity.
- Elemental mercury is poorly absorbed in the gut and is eliminated almost entirely in the feces making its ingestion generally harmless.

Conclusion

- This case demonstrates a suicide by gunshot wound to the abdomen.
- Interesting autopsy findings of what initially appeared to be another bullet.
- Actually mercury, which was ingested.

Acknowledgements

- Dr. Amy Gruszecki and American Forensics
- Sam Houston State University Forensic Science Department

References

1. Knight, Bernard. Explosive bullets: a new hazard for doctors. *British Medical Journal*. 1982; 284: 768-769
2. Swift, B, Ruttly, GN. The exploding bullet. *J Clin Pathol*. 2004; 57: 108: 107-112.